



Chapter 7

GUNSHOT WOUNDS

KEY FIGURES:

Entrance/exit wounds

This chapter describes how to treat the external, surface wounds caused by a bullet. The evaluation for underlying injury related to gunshot wounds in an extremity also is discussed. A plastic surgeon is often called to help manage such injuries.

The evaluation of a patient with chest, abdomen, or head/neck gunshot wounds is beyond the scope of this text. However, chapter 5 addresses the initial evaluation of any patient who has sustained a significant traumatic injury.

Initial Treatment of Stable Patients

By definition, a stable patient is awake and alert with stable vital signs. Especially in patients with a gunshot wound, it is preferable that a general surgeon or experienced emergency physician complete a full evaluation before your arrival to ensure that the patient is truly “stable.”

Expose the Injured Area

You need to evaluate the injured area thoroughly. All clothing should be removed to ensure that no injury is missed and to allow you to estimate the trajectory (path) of the bullet. This information is important, because knowing the approximate course of the bullet helps you to determine the probability for injury to underlying structures.

Do not probe the wound blindly. Blind probing of the gunshot wound can be dangerous. It may dislodge the clot in an injured blood vessel that has stopped bleeding, thus leading to significant blood loss.

Radiographs

Especially when the gunshot wound is in an extremity, a radiograph is indicated to rule out an underlying fracture and to determine whether the bullet remains in the tissues. It is often helpful to mark the external bullet holes with a small metal object to identify the path of the bullet on the radiograph. Sometimes markers are available in the radiology department for this purpose. Otherwise, a paper clip can be taped to each of the bullet sites.

Neurovascular Exam

When the bullet traverses the path of a major nerve or blood vessel, check for signs of nerve or vascular injury.

- Check the circumference of the injured area. Is it becoming larger (an indication of ongoing bleeding), or is it essentially staying the same size?
- Check for pulses in the vicinity of and distal to the bullet wounds.
- Palpate nearby pulses for a thrill (vibration), and listen with a stethoscope for a bruit. Thrills and bruits may be signs of arterial injury, even if a pulse is palpable.
- Adequate assessment of motor function is often difficult because of pain related to the traumatic injury, but always make the effort. Sensation should not be affected by pain. Test sensation in the extremity distal to the wound to evaluate for nerve injury.

Case Example

A patient arrives with a gunshot wound to the upper thigh. After removing his trousers and undergarments, you note one bullet wound along the inner aspect (medial side) of the thigh, about 15 cm from the pubic symphysis. The thigh is swollen but does not feel very tight. There is no active bleeding from the wound, and the thigh is not increasing in size.

A **radiograph** shows a bullet lodged in the soft tissues of the upper lateral thigh, and small fragments are noted in the soft tissues anterior to the femur. There is no fracture of the bone. This radiograph tells you that the bullet traversed the soft tissues in front of the femur where the femoral artery and femoral nerve travel. You must evaluate the patient for injury to these structures.

Feel the femoral pulse. Does it feel as strong as the opposite, uninjured femoral pulse? Can you feel a thrill with pulsation? Place your stethoscope over the pulse. Can you hear a bruit?

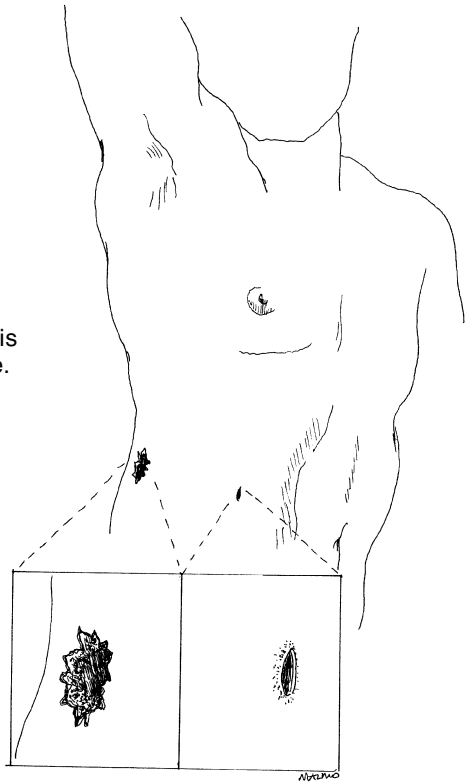
Feel for the distal pulses of the popliteal artery (behind the knee), dorsalis pedis artery (top of the foot), and posterior tibial artery (behind the medial malleolus). The popliteal artery often is difficult to find even in uninjured patients.

Check motor function of the femoral nerve. Can the patient extend the knee? Extension may be difficult because of pain in the thigh. The patient should be able to move his toes and ankle. These functions are under the control of the sciatic nerve, which travels along the posterior aspect of the thigh.

Check sensation. The femoral nerve is responsible for sensation to the anterior and medial aspects of the thigh. Touch the patient with your hand or with the end of a clean needle. Can he feel the touch?

If you identify a problem, further studies (possibly an arteriogram for an injured vessel) or exploration is warranted. The care of this patient then should be **transferred to a specialist**.

Typically the entrance wound is smaller and tidier than the exit site.



Care of the External Wound

The amount of injury at the entrance and exit (if present) sites is related to the caliber of the bullet, the angle at which the bullet traverses the tissues, the distance from the gun, and even the type of bullet. Usually, there is more damage to the skin at the exit site than at the entrance site (see figure on preceding page).

Excision of the edges of *all* bullet wounds used to be recommended, but now it is not always necessary.

When the bullet wound is relatively clean: Often the entrance wound is very clean, with regular skin edges and no gunpowder imbedded in the surrounding skin.

- Clean the area well with gentle soap and water or an antibacterial scub solution. Then rinse with saline. The wound then may be covered with gauze. If necessary, anesthetize the area with lidocaine before cleansing.
- Such wounds should not be closed primarily (i.e., with sutures).
- Wet-to-dry dressings or antibiotic ointment with dry gauze should be applied 1–2 times/day until the wound has healed.
- Oral antibiotics are not needed.

When the bullet wound has irregular edges embedded with foreign material: Risk for infection is high. Excision of the skin edges is indicated to minimize the risk.

How to Excise the Skin Edges

1. Infiltrate the area around the wound with local anesthetic.
2. Use a scalpel to excise the necrotic skin. Remove only the tissue that is purple or black (i.e., seems dead).
3. If gunpowder is embedded in surrounding skin, which otherwise looks alive, use the flat edge of the scalpel to scrape off the foreign material. Alternatively, use a forceps to grab the debris, and cut it out with the scalpel.
4. Remove any dead fat or subcutaneous tissue visible in the wound.
5. The wound should not be closed primarily. Treat the wound as previously described.

Gunshot Wounds to the Face

Gunshot wounds to the face should be cleansed as described above. Because of the cosmetic concerns, most facial wounds should be

loosely closed to reduce the amount of subsequent scarring. Full-thickness wounds (i.e., wounds that communicate with the oral cavity or go down to bone) must be closed in layers. See chapter 16, "Facial Lacerations" for specific details.

Do You Need to Remove the Bullet?

Contrary to television medical shows, the presence of a bullet in the soft tissues, in and of itself, is not an absolute indication for surgery. Operations are required to repair underlying injured structures, not specifically to remove the bullet, unless it is near an important structure and may cause trouble if it migrates.

In certain cases, however, the bullet must be removed. These exceptions are related to the nature of the ammunition. For this reason it is important to have information about the type of gun and bullet that caused the injury.

A **shotgun/buckshot injury** causes a great deal of damage to underlying soft tissue, and numerous pellets and foreign debris are lodged in the tissues. Most importantly, wadding is part of the ammunition and often becomes lodged in the soft tissues along with the pellets. Shotgun/buckshot injuries warrant exploration to remove dead tissue, to remove as many of the pellets as possible, to remove the wadding, and to wash out the wound. If such exploration is not done, the risk for serious infection is high.

It may be tempting to try to remove a single bullet that on radiographs does not seem too deeply embedded in the tissues. If the bullet cannot be easily palpated in the superficial skin, removal is not recommended. Removal is always more difficult than you think, and you risk injury to surrounding structures. It is usually best to leave the bullet alone. Over time, the bullet will either be walled off by the body and stay in place, causing no subsequent problems, or gradually work its way to the surface. Once the bullet can be felt directly under the skin, it can be removed easily with local anesthetic.

Bibliography

1. Fackler ML: Civilian gunshot wounds and ballistics: Dispelling the myths. *Emerg Med Clin North Am* 16:17–28, 1998.
2. Modrall JG, Weaver Fam Yellin AE: Diagnosis and management of penetrating vascular trauma and the injured extremity. *Emerg Med Clin North Am* 16:129–144, 1998.