

Chapter 17

PRESSURE SORES

KEY FIGURES:

Pressure sore
Sacral pressure sore

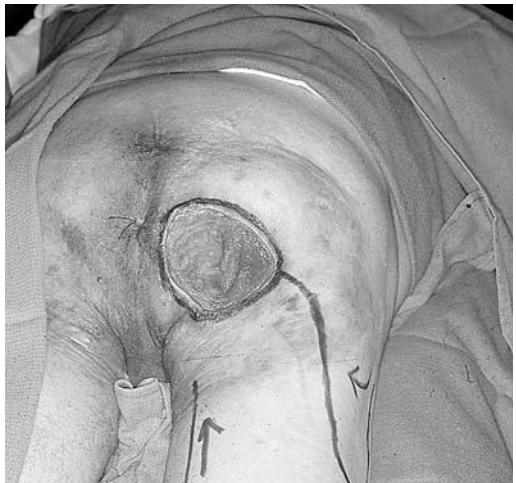Trochanteric pressure sore
Ischial pressure sore

Pressure sores are chronic wounds caused by prolonged pressure applied to a specific area of the body. The involved tissue usually overlies a bony prominence. When a pressure sore develops because the patient is in the recumbent position for long periods, it is called a **decubitus ulcer**.

Pressure sores are often large wounds and may seem difficult to manage. However, by combining the wound care knowledge from previous chapters with the information given here, you will find these wounds more manageable. Often they can be treated successfully with debridement of necrotic (dead) tissue and local wound care measures alone. The result is a healed wound.

Only in specific instances is a flap indicated for the treatment of a pressure sore.

Large ischial pressure sore.
(Photo courtesy of Jeffrey Antimarino, M.D.)



Causes of Pressure Sores

The basic problem that leads to the development of a pressure sore is application of elevated pressure to soft tissue for too long a time. The pressure causes direct injury to the tissues. Unrelieved pressure elevation for as little as 2 hours can cause permanent tissue injury and subsequent tissue death.

People at Risk

Communication between the central nervous system and the body (via the peripheral nervous system) allows detection of elevated pressure at the tissue level. Feedback mechanisms result in the diminution of pressure so that tissue injury does not occur. People who are ambulatory and without neurologic abnormalities make regular, subtle position changes without conscious effort because of these feedback mechanisms. Thus, under normal circumstances, people do not develop a pressure sore when they sleep in a recumbent position for several hours.

Any condition that prevents these subtle position changes or interferes with the communication between the central nervous system and peripheral nervous system places the person at risk for the development of a pressure sore.

Patient Populations at High Risk

- **Paraplegic or quadriplegic patients**, who usually are wheelchair-dependent or bedridden and need help in changing positions. They also may lack the ability to sense an elevation in tissue pressure when they remain in the same position for too long a time.
- **Patients with decreased sensation due to neurologic disorders.** For example, children with meningomyelocele have diminished sensation below the spinal cord abnormality. Thus, the central nervous system cannot monitor the pressure in the insensate areas.
- **Patients with impaired mental capacity.** Patients with severe dementia or patients who have suffered debilitating head injuries are often bedridden and move very little when left alone.
- **Seriously ill patients in an intensive care unit.** Patients who have sustained serious burns or multiple fractures are particularly at risk. They are often in considerable pain, which may be exacerbated by movement. Thus they tend to stay in one position unless assisted by a caregiver. In addition, pain medications keep them drowsy, which also inhibits movement.

Additional Risk Factors

- **Malnutrition** makes the tissues more prone to injury. It also delays wound healing.
- **Incontinence** can cause the skin in the buttocks and perineal area to be chronically moist. The tissues become macerated and more susceptible to breakdown with minimal trauma. In addition, contamination of an open wound with urine and feces interferes with wound healing.
- **Tobacco use.** The nicotine in tobacco decreases circulation to tissues, thus exacerbating the lack of circulation caused by the effects of pressure on the tissues. Tobacco use also contributes to poor wound healing.

Table 1. Areas Prone to the Development of Pressure Sores

Area of Body	Underlying Bony Prominence	Comments
Base of buttocks	Ischium	Tends to occur in patients confined to wheelchair and in seated position for much of the time
Upper outer thigh	Greater trochanter	Tends to occur in patients who spend prolonged periods in bed
Heel of foot	Calcaneus	May occur in both of above patient populations
Back of head	Occiput of skull	Tends to occur in patients who spend prolonged periods in bed
Lower back	Sacrum	Tends to occur in patients who spend prolonged periods in bed

Prevention

For patients at high risk for developing a pressure sore, prevention is the key. To avoid the development of pressure sores in bedridden patients, encourage the patients (and their caregivers) to change positions regularly (*at least* every 2 hours). Paraplegic patients who spend prolonged periods in a wheelchair should lift themselves off their buttocks for just a few seconds every 15 minutes.

Cushioning of pressure points is also important. For example, place pillows or cushions between the patient's knees and ankles to prevent pressure in these areas. Have the patient sit on a pillow as well. Special pressure-dissipating cushions can be fitted to the patient's wheelchair.

Cessation of smoking and maintenance of adequate nutrition are vital for prevention. Proper hygiene of the buttocks and perineum is also important.

Pressure Sore Staging System

A staging scale is important for documentation and communication. Recognition of a pressure sore in its early stages allows aggressive intervention, which may prevent the development of a large, full-thickness wound.

The staging system is based on skin appearance. However, the skin is much more resistant to the effects of pressure than the underlying fat and muscle. Thus by the time you see significant changes in the skin, damage has already occurred in the underlying soft tissue fat and muscle. You must institute treatment measures quickly.

- Stage I** Redness of intact skin that does not blanch (when you press on the area the redness does not go away). Earliest stage, before start of skin breakdown.
- Stage II** Partial-thickness skin loss involving the epidermis and dermis. The ulcer is superficial and may look like a blister or shallow crater.
- Stage III** Full-thickness skin loss involving the underlying subcutaneous fat but not the muscle.
- Stage IV** Full-thickness skin loss with extensive destruction, tissue necrosis, or damage in muscle, bone, or supporting structures (e.g., tendon, joint capsule).

From U.S. Department of Health and Human Services: Pressure Ulcers in Adults: Prediction and Prevention. Clinical Practice Guideline No. 3, Publication 97-0047, 1992.

Treatment

All Patients in the Process of Developing a Pressure Sore

1. Reinforce the necessity of regular position changes to patient and caregivers.
2. Institute measures to relieve the pressure in the at-risk area. Pillows, foam mattresses, and foam splints are useful.
3. Proper nutrition is a must. High-protein drinks and puddings are useful. Supplemental vitamins and minerals also should be given (especially vitamin C and zinc).
4. Patients should remain active. They should *not* be placed on bed rest or kept from their usual activities.
5. The patient should refrain from using tobacco products.
6. The wound should be kept free from urine or fecal contamination. Temporary use of a Foley catheter (or intermittent catheterization)

should be considered. A diverting colostomy should be considered if persistent fecal contamination is a problem.

Stage I or II Pressure Sore

1. Keep the affected tissue clean and the surrounding area dry.
2. Apply antibiotic ointment (e.g., Bacitracin, silver sulfadiazine) daily to areas that have blistered.
3. DuoDERM (also called Granuflex or Varihesive) is a useful dressing alternative for the treatment of a relatively superficial pressure sore. Cut it to the proper size (a little larger than the wound), and place it directly over the injured tissue. You may need to put tape around the edges to keep it in place. DuoDERM promotes healing by providing a moist environment for the injured tissue. This dressing often may be left in place for up to 7 days, which makes it convenient for patients and caregivers.

Stage III or IV Pressure Sore

If the wound is covered with a dry, dark, leathery eschar (scab): If the wound has no surrounding cellulitis and no drainage, *leave it alone*. This dry eschar is easy to care for. Clean the area with saline or povidone-iodine solution daily. You may cover the wound with dry gauze if the patient desires. The underlying tissues will gradually heal, and the eschar will separate and detach. The eschar should be removed if signs of infection (e.g., redness, warmth, fever) are present.

If the wound has a red, granulating base but is covered with areas of gray exudate: Apply wet-dry saline dressing changes at least twice daily, if possible. Once the wound is clean, you may change to wet-wet dressings, an antibiotic ointment with dry gauze dressings, or other topical material.

If the wound contains foul-smelling, necrotic tissue: Surgical debridement (described below) is necessary to remove large amounts of dead tissue. Follow with wet-dry dressings, using saline or preferably Dakin's solution to clean the wound and promote healing.

If the wound is surrounded by cellulitis: Red, warm, and indurated skin around the pressure sore indicates an infection in the soft tissues (cellulitis). Treat the patient with a course of antibiotics. Ordinarily, a pressure sore without signs of surrounding tissue infection does not require antibiotics. Use antibiotics only if the wound is infected.

With the above treatments, most pressure sores heal on their own. The key is to institute treatment early, before the wound gets out of control. Serial debridement of necrotic tissue and the above treatments

promote gradual healing even of a large pressure sore. Although it may take weeks to months for the wound to close completely, this is the optimal course of treatment for a pressure sore. On rare occasions, local flaps can be used to obtain wound closure (see descriptions below).

Surgical Intervention

Surgical intervention is required when the wound has so much dead tissue that formal debridement is needed to clean the wound. Occasionally, the wound can be closed with a local flap.

Debridement

Debridement of small, necrotic areas can be performed at the bedside. But for large or deep wounds, it is better to do the debridement in the controlled environment of the operating room.

The patient will lose blood when large amounts of dead tissue are cut away. Be sure to check the patient's hemoglobin/hematocrit before debriding a large pressure sore. A transfusion may be required.

Often the patient has no feeling in the area of the pressure sore. Sedation (to allay fears and increase comfort on the operating table) may be all that is needed.

Using a scalpel (or a scissors) and forceps, cut away all dead tissue.

If the tissue bleeds, it is probably healthy; if it does not bleed, it is probably dead.

Dead bone or tendon in the wound must be removed. Place a clamp on the tendon, and put the tendon under tension (i.e., pull on the clamp). Then cut off all of the exposed tendon. Bone can be removed with a bone rongeur or an osteotome. Remove the outer layers of the exposed bone until you reach bleeding bone.

Clean the wound with saline mixed with a small amount of povidone-iodine solution if available, and pack the wound with a gauze dressing. Leave the dressing in place for 24 hours. Then remove the packing, and start regular wet-dry dressings.

Debridement may be repeated (serial debridement) if, because of concerns about blood loss, all necrotic tissue cannot be removed at one time.

Local Flaps

Closing a pressure sore with a local flap is an advanced treatment that requires surgical expertise. A local flap is not indicated for all pressure

sores. Most heal with local care. Unless you are particular about whom you operate on, the risk for recurrence of the pressure sore is quite high (often over 50%).

If you perform a flap on a patient who is not a good surgical candidate (e.g., a patient who is malnourished, actively smoking, or noncompliant with position changes), he or she may end up not only with a recurrent pressure sore but also with a poorly healing donor site.

Indications

Specific reason for development of the pressure sore. For example, a paraplegic patient who has had no previous pressure sores (despite being in a wheelchair for 10 years) but develops one when he or she is hospitalized for pneumonia and unable to change positions.

Excellent nutritional status. Albumin > 3.5 gm/dl, prealbumin > 20 mg/dl, transferrin > 250 mg/dl (2.5 gm/L). If the patient is malnourished, the flap will not heal and surgery is pointless. There is also a high risk that the donor site will heal poorly.

The patient must not smoke.

Highly motivated patients who want to be at home. Some patients live alone or have little home support. They may be unable to go home because of concerns about wound care. If patients in this situation meet the nutritional requirements and show that they are motivated enough to change positions regularly, local flap closure may be indicated.

Preoperative Considerations

Before flap closure, the pressure sore must be debrided thoroughly. It is often useful to debride the wound surgically a day or so before the planned flap. All necrotic tissue and dead bone must be removed.

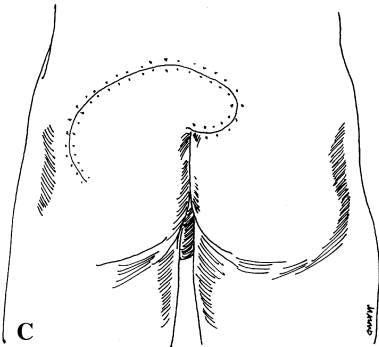
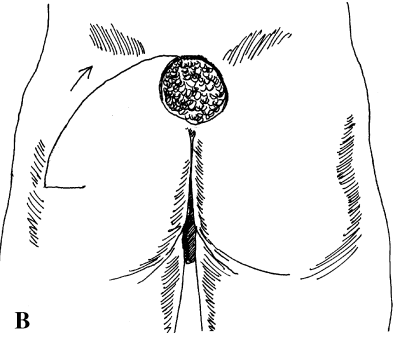
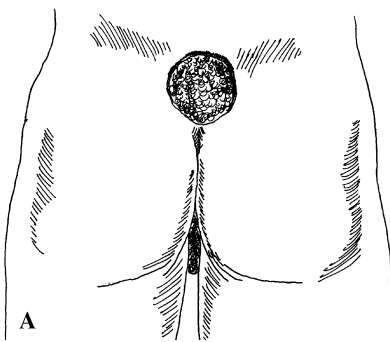
Caution: Debridement of pressure sores and flap closure can lead to significant blood loss. The patient's hematocrit must be above 27 (hemoglobin at least 8–9), and blood must be available for the operating room.

A closed suction drain should be available to place under the flap to prevent fluid accumulation postoperatively. If a closed suction drain is not available, a passive drain (Penrose drain or a piece of sterile glove) should be placed under the flap. See chapter 13, "Local Flaps," for additional information.

Sacral Pressure Sores

Buttocks Rotation Flap

1. Draw the flap before making any incisions. This step allows you to make corrections.
2. Design the flap larger than you think you will need to ensure a tension-free closure.
3. Design the flap so that it extends in a curvilinear fashion superiorly (a few cm) and laterally from the wound. It should have a wide base (at least 8–10 cm).
4. Separate the flap from the underlying tissues and transfer it into the wound. Undermine the surrounding skin edges as needed to allow the flap to be sutured in place without tension.
5. If necessary, a small back cut can be made at the lateral edge of the base of the flap to help it turn into the wound. Do not narrow the base more by more than 1–2 cm.



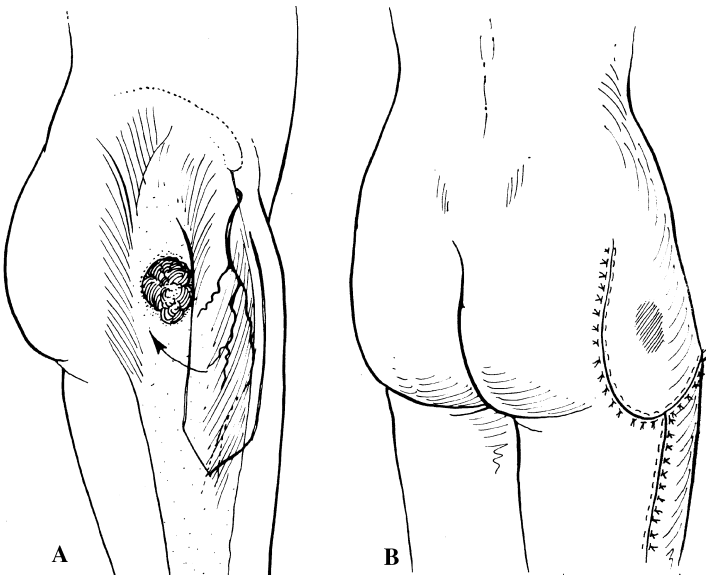
A, Sacral pressure sore. B, Diagram of inferiorly based sacral rotation flap. C, Flap rotated and sutured into position.

6. Suture the flap in place over a drain. Place a few dermal sutures, and then do an interrupted skin closure. The skin closure should not be tight. It is better to have little gaps in the closure, which will heal, than to do a tight closure and lose part of the flap.

Trochanteric Pressure Sores

Tensor Fascia Lata Flap

The tensor fascia lata (TFL) flap is the most commonly used flap for closure of a trochanteric pressure sore. The TFL flap is adjacent to the wound and runs anterior to it, along the lateral aspect of the thigh. The widest donor defect that can be closed primarily is approximately 6 cm. Pinch the thigh tissues to see how much skin you should be able to remove while still being able to close the donor site primarily. The flap is composed of the skin and fascial extension from the TFL muscle.



A tensor fascia lata flap is the best choice for coverage of a trochanteric pressure sore. A, Outline of tensor fascia lata musculocutaneous flap. B, Tensor fascia lata flap used to reconstruct trochanteric pressure sore. (From Jurkiewicz MJ, et al (eds): *Plastic Surgery: Principles and Practice*. St. Louis, Mosby, 1990, with permission.)

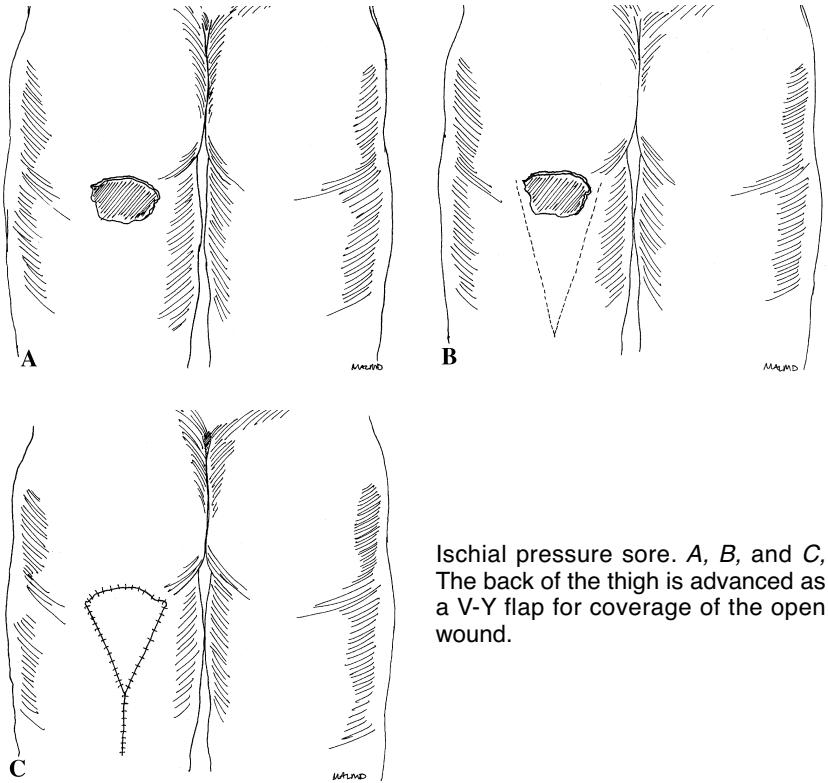
1. Draw the flap before making any incisions. This step allows you to make corrections.
2. The anterior border of the flap is a line drawn from the anterior superior iliac spine to the lateral margin of the kneecap.
3. The posterior border is about 5 cm posterior to the anterior border.
4. The flap can extend inferiorly to within 10 cm of the kneecap.
5. The skin is incised, and the incision is taken down through the subcutaneous tissue to the underlying thick TFL fascia. The fascia stays attached to the flap.
6. Elevate the flap off the underlying tissues. You will see an obvious separation between the undersurface of the TFL fascia and the deeper tissues. It is useful to place a stitch in the distalmost part of the flap to connect the fascia to the skin so that you do not accidentally separate the skin/subcutaneous tissue from the TFL fascia during dissection.
7. The flap is moved into the wound defect and loosely sutured in position. Place a few dermal sutures, and then do an interrupted skin closure. The skin closure should not be tight. It is better to have little gaps in the closure, which will heal, than to do a tight closure and lose part of the flap.
8. The donor site is closed primarily with dermal sutures and interrupted skin sutures. A suction drain or a passive drain should be placed under the skin closure at the donor site as well as the site of the pressure sore.

Ischial Pressure Sores

Posterior Thigh Flap

The posterior thigh flap is a V-Y advancement flap. It is quite useful for covering large ischial pressure sores (8–10 cm diameter). The pedicle of this flap is not a bridge of surrounding skin or subcutaneous tissue. The deep tissues underlying the flap supply the circulation.

1. Draw the flap before making any incisions. This step allows you to make corrections.
2. Mark the V with the widest area at the lower edge of the pressure sore, tapering gradually to a point. The V should go at least half way down the back of the thigh.
3. Incise the skin edges going through the subcutaneous tissue down to (but not into) the underlying muscle.



Ischial pressure sore. A, B, and C, The back of the thigh is advanced as a V-Y flap for coverage of the open wound.

4. You should be able to advance the flap superiorly into the wound defect. Place a drain at the base of the wound.
5. Close the narrow part of the V flap defect primarily. This step creates the Y limb.
6. Suture the flap loosely, under no tension. Place a few dermal sutures, and then do an interrupted skin closure. The skin closure should not be tight. It is better to have little gaps in the closure, which will heal, than to do a tight closure and lose part of the flap.

General Postoperative Care for the Above Procedures

1. Cleanse and apply antibiotic ointment to the suture lines daily.
2. If a suction drain was used, it should stay in place until the drainage is < 50 ml in 24 hours. Try to keep it in place at least 1 week. If you do not have a suction drain, remove the passive drain after 3–4 days.

3. In general, the patient should apply no pressure to the surgical site until the suture line has healed (usually 2–3 weeks). The patient then should be allowed to place weight over the area for limited periods (10–15 minutes 3 or 4 times daily). If the suture line stays intact (i.e., it does not start to separate), gradually decrease the restrictions on positioning.
4. Leave the skin sutures in place for at least 14 days unless there are signs of irritation from the sutures.

Bibliography

1. Cervo FA, Cruz AC, Posillico JA: Pressure ulcers: Analysis of guidelines for treatment and management. *Geriatrics* 55(3):55–60, 2000.
2. Disa JJ, Carlton JM, Goldberg NH: Efficacy of operative cure in pressure sore patients. *Plast Reconstr Surg* 89:272–278, 1992.
3. Hopkins A, Gooch S, Danks F: A programme for pressure sore prevention and management. *J Wound Care* 7:37–40, 1998.