



Chapter 24

BREAST SURGERY

KEY FIGURES:

Saline implant reconstruction
Latissimus dorsi reconstruction
Free TRAM reconstruction

In the developed world, breast reconstruction after mastectomy and breast reduction (reduction mammoplasty) are common reconstructive procedures. They require a combination of artistic and technical skills, which can be obtained only through many years of surgical training.

Because of their highly technical nature, no specific procedures are discussed in detail. Instead, this chapter offers basic information.

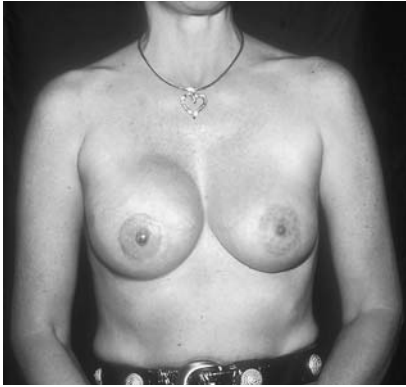Breast Reconstruction

Evolution of Procedures

Over the past 25 years, because of advances in plastic surgical techniques, the esthetic quality of breast reconstruction has improved greatly. Before the early 1970s, breast reconstruction was a multistaged procedure in which a distant random flap was transferred to the chest in a series of operations. The results were not always successful, nor were the reconstructed breasts consistently cosmetically pleasing.

Snyderman and Guthrie reported the use of a silicone implant for breast reconstruction in 1971. Their achievement was remarkable because for the first time a breast was reconstructed in a single procedure. Although it was not necessarily a cosmetic triumph, patients were so pleased to have a breast after one operation that they considered the procedure worthwhile.

Implant reconstruction is still a popular option for breast reconstruction, although now saline implants are used. To achieve the best aesthetic result, implant reconstruction is often not a single procedure. Initially, a tissue expander (a modified implant to which the surgeon



Breast reconstruction with a saline implant. Nipple-areolar reconstruction also has been completed. (Photo courtesy of Nelson Goldberg, M.D.)

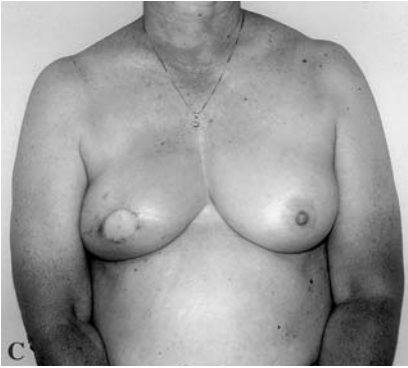
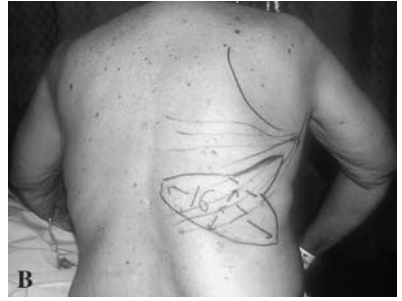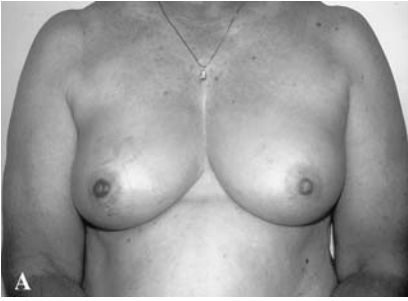can add saline in the office) is placed under the chest wall muscles and skin. The expander is then gradually filled with saline to stretch the tissues of the chest. Thus, an implant large enough to match the opposite breast eventually can be placed. Expansion usually takes several months to complete, and a second operation is required to replace the expander with the permanent implant.

Implant breast reconstruction has its drawbacks. Because the implant is a foreign body, risks include infection, implant deflation, and distortion of the reconstructed breast. It is also difficult to create a droopy breast with an implant. Because of these limitations, other reconstructive options were developed.

In the late 1970s, axial musculocutaneous flaps enhanced a patient's reconstructive options. These flaps (composed of muscle and overlying skin and subcutaneous tissue) could be designed for use in breast reconstruction. The use of a muscle flap allows creation of the reconstructed breast from the patient's *own tissues*.

The **latissimus dorsi flap** (a flap using tissue from the back) became a popular reconstructive option. However, only a relatively small sized breast can be reconstructed with this flap, so an implant may still be needed to attain symmetry in a large-breasted woman. The advantage of this procedure is that even if an implant is needed, the breast can be reconstructed in one operation. The latissimus dorsi flap with or without an implant remains a viable reconstructive option.

In the mid 1980s, Carl Hartrampf popularized the pedicle **TRAM flap** for breast reconstruction. TRAM stands for transverse rectus abdominis (the paired muscles that are vertically oriented on the abdomen and run on either side of the umbilicus) myocutaneous flap. This procedure often is called the "tummy tuck" breast reconstruction.



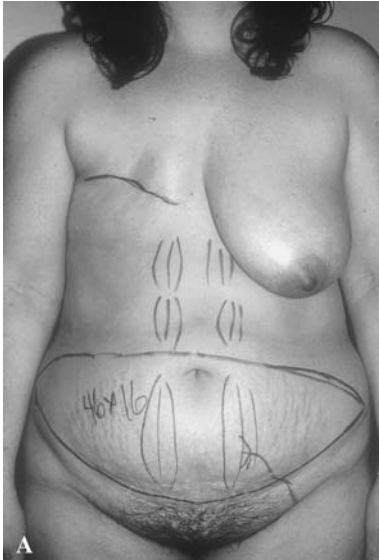Latissimus dorsi flap. *A*, Patient with Paget's disease of the right breast. *B*, The patient underwent a skin-sparing mastectomy; only the nipple and areolar skin were removed with the underlying breast tissue. The breast was reconstructed immediately with a latissimus dorsi musculocutaneous flap. The flap is drawn on the patient's back. *C*, Final result before nipple reconstruction.

The pedicle TRAM flap is composed of the lower abdominal skin and subcutaneous tissue, which remains attached to the rectus abdominis muscle. The blood supply comes from the superior portion of the muscle. The TRAM flap allows creation of a larger breast (compared with the latissimus dorsi flap) without the need for an implant.

The pedicle TRAM flap is still a popular reconstructive technique, but the procedure does have limitations. Under some circumstances and in some patient populations (diabetics, smokers, and obese patients), an unacceptably high rate of partial flap loss has been noted.

Because of these limitations, researchers performed cadaver dissections to more fully evaluate the blood supply to the TRAM flap. These studies demonstrated that the tissues making up the TRAM flap are better supplied by the deep inferior epigastric artery and inferior rectus muscle (as opposed to the deep superior epigastric artery and superior rectus muscle used in the pedicle TRAM technique). Microsurgeons now perform breast reconstruction using the TRAM as a free flap based on the deep inferior epigastric vascular circulation. Because of its better blood supply, the free TRAM flap overcomes most of the limitations of the pedicle TRAM.

Currently free TRAM breast reconstruction offers the best way to make a large breast in one operation using the patient's own tissues. The drawback is that not all plastic surgeons have the technical skills required to perform microsurgery.



Free TRAM breast reconstruction. *A*, Preoperative markings show the amount of abdominal wall tissue to be removed. The rectus muscles and vascular pedicle also are drawn to show the underlying anatomy. *B*, Completed re-

Reconstruction of the Nipple and Areolar Complex

The above procedures describe the creation of the breast mound. The nipple and areolar complex usually are reconstructed in a second, relatively minor procedure.

Small flaps of tissue from the breast mound are used to create a nipple. Sometimes a full-thickness skin graft is required as well. A tattoo machine is used to add pigment to the nipple and surrounding skin to complete the reconstruction of the nipple and areolar complex. This procedure often can be done in the surgeon's office.

Timing of Breast Reconstruction

Breast reconstruction can be done at the time of mastectomy (immediate reconstruction) or at almost any time after the mastectomy (delayed reconstruction). The advantage of an immediate reconstruction is that the patient awakens from the mastectomy with a reconstructed breast. Avoidance of an extended period with a flat, scarred chest is an important psychological boost for some patients.

Because of concerns that reconstruction may interfere with surveillance for recurrent breast cancer, general surgeons initially were hesitant to refer patients for immediate breast reconstruction. Studies have shown that these concerns are unwarranted. Immediate breast reconstruction does not interfere with surveillance or mask evidence of recurrent disease.

Some patients may not be appropriate candidates for immediate reconstruction because of the extent of disease or concerns that postoperative radiation or chemotherapy may affect the reconstruction. Delayed reconstruction is always an option and can be performed months or even years after cancer treatments have been completed. The timing of breast reconstruction is ultimately decided on an individual basis after thorough discussion between the patient and her doctors.

Currently, women with breast cancer have many options for breast reconstruction. Depending on the patient's reconstructive needs and expectations, the prognosis for obtaining a matched pair of breasts after mastectomy is excellent.

Breast Reduction

Large, pendulous breasts (D–DDD or even larger cup sizes) can be a source of embarrassment for some women and also may cause significant neck, upper back, and shoulder pain. These symptoms can significantly interfere with their ability to work.

Breast reduction (reduction mammoplasty) decreases the size of the breasts, so that they are more appropriately proportioned to the patient's body habitus. Attaining an aesthetically pleasing result is a high priority.

Classically, this procedure involves large incisions to remove excessive breast tissue and to reposition the nipple and areolar complex. These incisions result in long scars (around the areola, from the areola to the inframammary fold, and along the inframammary fold). These scars can be problematic as well as noticeable. Other complications of breast reduction include loss of nipple sensation, inability to breast feed, and loss of the nipple/areolar complex. Despite these risks, most women who undergo breast reduction are quite pleased with the results.

To obviate the need for such large incisions and to decrease the risks for other complications, liposuction is beginning to be included in the operative technique. Currently, plastic surgeons are developing other modifications to decrease the risks inherent in breast reduction.

Gynecomastia

Gynecomastia is the term for abnormal enlargement of the male breast. It is commonly encountered in pubescent males or older men because of hormonal considerations. Gynecomastia associated with puberty usually resolves within a few years; no surgery should be considered until the patient is at least 19 or 20 years of age.

When evaluating a patient with gynecomastia, be sure to get a thorough medical history. Medications associated with gynecomastia include cimetidine, spironolactone, digitalis, and reserpine. Be sure to inquire about recreational drug use because marijuana also has been implicated.

You must examine the patient's testicles to rule out the presence of a testicular tumor, which may produce hormones responsible for breast enlargement. Especially with unilateral enlargement or when a discrete breast mass is palpable, you must rule out the possibility of an underlying breast cancer. (Yes, men can get breast cancer). Blood tests to evaluate the levels of various hormones also should be done.

Gynecomastia is quite challenging to treat. Simple mastectomy used to be the treatment of choice, but esthetic considerations make it a poor option. Currently, liposuction with or without additional formal excision of breast tissue (using a small incision along the areola) is the treatment of choice and has resulted in a markedly improved esthetic outcome.

Bibliography

Breast reconstruction

1. Hartrampf CR, Schefflan M, Black PW: Breast reconstruction with a transverse abdominal island flap. *Plast Reconstr Surg* 69:216–225, 1982.
2. Maxwell GP: Latissimus dorsi breast reconstruction: An aesthetic assessment. *Clin Plast Surg* 8:373–387, 1981.
3. Schusterman MA: The free TRAM flap. *Clin Plast Surg* 25:191–195, 1998.
4. Slavin SA, Schnitt SJ, Duda RB, et al: Skin-sparing mastectomy and immediate reconstruction: Oncologic risks and aesthetic results in patients with early-stage breast cancer. *Plast Reconstr Surg* 102:49–62, 1998.
5. Snyderman RK, Guthrie RH: Reconstruction of the female breast following radical mastectomy. *Plast Reconstr Surg* 47:565, 1971.
6. Spear SL, Majidian A: Immediate breast reconstruction in two stages using textured, integrated valve tissue expanders and breast implants: A retrospective review of 171 consecutive breast reconstructions from 1989–1996. *Plast Reconstr Surg* 101: 53–63, 1998.

Breast reduction/Gynecomastia

7. Hammond DC: Short scar periareolar inferior pedicle reduction (SPAIR) mammoplasty. *Plast Reconstr Surg* 103:890–901, 1999.
8. Hidalgo DA: Improving safety and aesthetic results in inverted T scar breast reduction. *Plast Reconstr Surg* 103:874–886, 1999.
9. Lejour M: Vertical mammoplasty: Update and appraisal of late results. *Plast Reconstr Surg* 104:771–781, 1999.
10. Rosenberg GJ: Gynecomastia. In Spear SL (ed): *Surgery of the Breast: Principles and Art*. Philadelphia, Lippincott Williams and Wilkins, 1998, pp 831–841.