Chapter 31

TRAUMATIC HAND AND FINGER AMPUTATIONS

KEY FIGURES:

Care of amputated segment
Amputation of the middle finger
Successful replantation

This chapter outlines the basic principles for the evaluation and treatment of traumatic hand and finger amputations proximal to the distal interphalangeal (DIP) joint. Amputations distal to the DIP joint can be treated as a fingertip injury (see chapter 29, "Fingertip and Nail Bed Injuries").

The procedure to reattach an amputated part is highly technical and tedious. It includes reconnecting blood vessels (both an artery and at least one vein), nerves, and lacerated tendons as well as realigning and stabilizing the bones. A highly trained microsurgeon with access to specialized equipment is required.

If No Properly Equipped Microsurgeon is Available

Your best strategy is to help the wound heal with as little functional disability as possible. You can take steps to prevent, for example, a painful stump, which will interfere with use of the hand.

Basic Wound Treatment

After administering a digital block or wrist block, as indicated by the level of amputation, completely clean and examine both the stump and the amputated part (see chapter 6, "Evaluation of an Acute Wound").

Exposed tendons that have lost their distal insertion sites should be cut off so that the ends of the tendons are covered by soft tissue.

Do not discard the amputated part until you have thoroughly examined the wound. You may be able to use some of the skin from the amputated segment as a skin graft to cover the open wound.

Options for Wound Closure

If enough skin is available, close the wound with a few loose sutures. A tight closure can lead to further tissue loss.

If no skin is available, no bone or tendon is exposed, and the wound is relatively small (< 2 cm), the wound can be left open and treated with local care. An alternative is to use noninjured skin from the amputated segment as a full-thickness skin graft to cover the wound.

If the wound is large and cannot be closed primarily or if bones or intact tendons are exposed, a distant flap (e.g., chest flap, groin flap) is needed for wound closure. (See chapter 14, "Distant Flaps.")

If a nerve is exposed at the end of the stump, place a clamp on the nerve and pull gently. Then cut the nerve back to the point where it exits the soft tissues. This maneuver allows the nerve to retract under healthy skin or soft tissue and thus prevents development of a sensitive or painful stump.

Wound Care

Clean with gentle soap and water or sterile saline daily.

Strongly urge the patient not to smoke.

The patient should keep the affected hand elevated to decrease swelling and pain and to promote healing.

Remember pain medication. Acetaminophen alone may not be enough for the first few days after injury. Amputations can be quite painful.

Apply antibiotic ointment and a simple, dry dressing 1–2 times/day. Wet-to-dry dressings also can be useful.

- If the wound was sutured closed, after a few days the dressings can be discontinued.
- If the wound was left open, continue the dressing changes until the wound is healed.

Encourage the patient to move the finger and hand to prevent joint stiffness. Active and passive range-of-motion exercises also should be encouraged.

If a Properly Equipped Microsurgeon is Available

You can take several important steps before the patient is transferred to the microsurgeon's care. An amputated hand or finger(s) can be replanted even many hours after the injury, but the amputated part must receive proper care.

In addition, the patient must be informed that he or she will not awaken from surgery with a normally functioning hand. Replantation of the amputated segment commits the patient to a long and tedious rehabilitation program to obtain maximal hand function. Be sure to explain this prolonged process to the patient.

Patient Preparation

1. **Administer intravenous (IV) fluids** (normal saline or Ringer's lactate) to keep the patient hydrated. While awaiting surgery, the patient should not be allowed to eat or drink anything except required medications.
2. **Give aspirin** (*not* acetaminophen) at a dose of 80–160 mg, which is equivalent to one baby aspirin or one-half of an adult aspirin. It can be given by mouth or as a rectal suppository. The antiplatelet properties of aspirin may help to prevent clotting of the vessels after the reattachment has been completed.
3. **Give a dose of IV antibiotics.** A first-generation cephalosporin is most appropriate.
4. **Control pain** with IV morphine or a digital block. Give the nerve block only after consultation with the surgeon.
5. **Clean and dress the stump** with saline-moistened gauze (damp, not soaking wet), and wrap the stump lightly with dry gauze to control oozing and to keep the wound clean.
6. **Gently elevate** the affected hand.
7. **Get a radiograph** of the stump as well as the amputated segment.

Care of the Amputated Part

1. **Remove any foreign material** from the exposed soft tissues.
2. **Clean** the amputated part with saline, and **wrap** it in saline moistened gauze (damp, not soaking wet).
3. Place the wrapped segment in a **plastic bag**.
4. Place the bag into a **container filled with ice mixed with saline**. *Do not place the amputated part directly on ice.*
5. Do not forget to get a **radiograph** of the amputated part.

The patient is now ready for transfer.

Bibliography

Merle M, Dautel G: Advances in digital replantation. Clin Plast Surg 24:87–106, 1997.

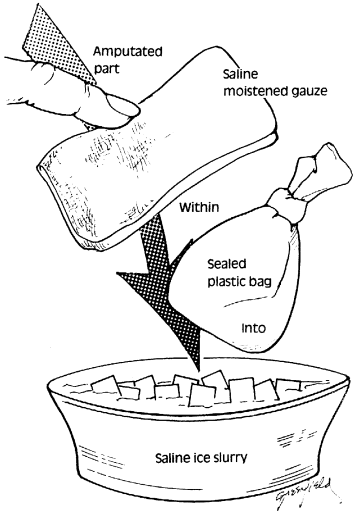

Care of the amputated segment. The amputated segment should be cooled immediately by wrapping it in a moist saline gauze, placing it in a sealed plastic bag, and immersing it in an iced saline container. (From McCarthy J (ed): Plastic Surgery. Philadelphia, W.B. Saunders, 1990, with permission.)

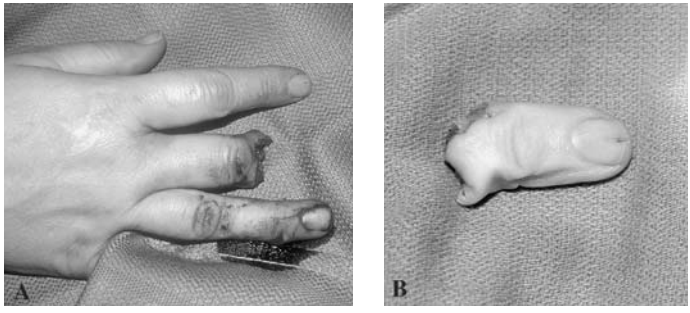

Traumatic amputation of the middle finger. *A,* Hand with missing finger. *B,* Amputated segment.

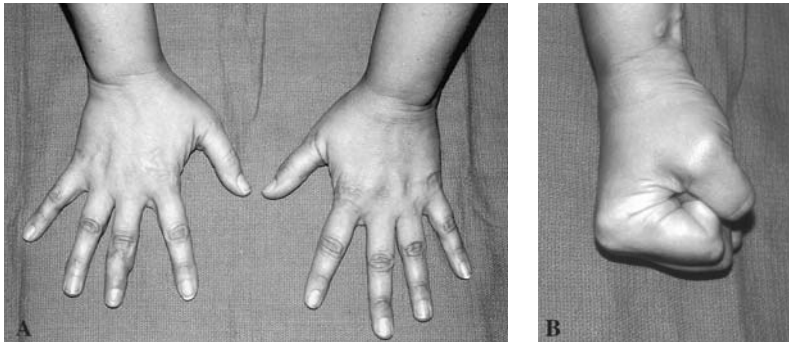

One year after successful replantation. *A* and *B*, Patient has regained excellent function of her hand.