

# SPECIFIC TYPES OF HAND INFECTIONS

### KEY FIGURES:

Felon  
Paronychia  
Collar button abscess

## *Felon*

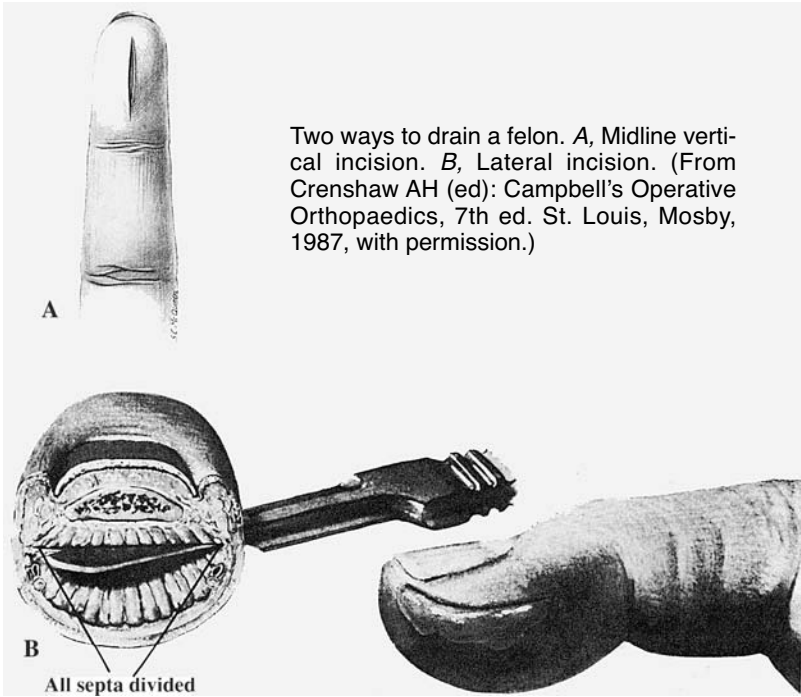
A felon is an abscess of the fingertip along the volar skin pad. The fingertip is swollen and quite painful. Without proper treatment, the infection can progress and cause serious complications. Necrosis of the fingertip skin, osteomyelitis (infection of the underlying bone), and even flexor tenosynovitis (see description later in this chapter) may result.

If the infectious process is caught before abscess formation, it can be treated with antibiotics alone. If no improvement is observed with antibiotics or if fluctuance is present, incision and drainage are necessary.

### *Incision and Drainage*

1. Anesthetize the finger with a digital block using lidocaine, bupivacaine, or a mixture of the two.
2. Clean the fingertip with some type of antibacterial agent.
- 3A. If the “point” (i.e., area of maximal tenderness and fluctuance) is on the volar fingertip pad, make a longitudinal incision over this point. Take care to keep the incision distal to the distal interphalangeal (DIP) flexion crease.
- B. If the “point” is on the lateral surface, make a longitudinal incision on the ulnar side of the digit (radial side for the thumb or little finger) parallel to the expected position of the digital nerve. Take care to keep distal and dorsal to the DIP flexion crease to prevent injury to the digital nerve and artery.
4. Use a clamp to open the incision and thoroughly drain the space.

5. If you have access to a microbiology lab, send a specimen of the pus for culture to identify the causative organism.
6. Irrigate the abscess cavity with sterile saline.
7. Pack a small piece of gauze into the cavity, and cover the fingertip with dry gauze.



### *Aftercare*

- Keep the hand elevated.
- Remove the packing the next day, and clean the finger with gentle soap and water or saline.
- If possible, repack the cavity with saline-moistened gauze. Change this dressing 1 or 2 times each day.
- Once you cannot pack the cavity with gauze, simply apply antibiotic ointment to the area and cover with a dry gauze 1 or 2 times each day.
- Be sure to wash the finger with gentle soap and water or saline twice daily.

- Encourage active and passive range-of-motion exercises to prevent the finger from becoming stiff.
- Continue the oral antibiotics for several days, until the tenderness and redness resolve.

## ***Paronychia***

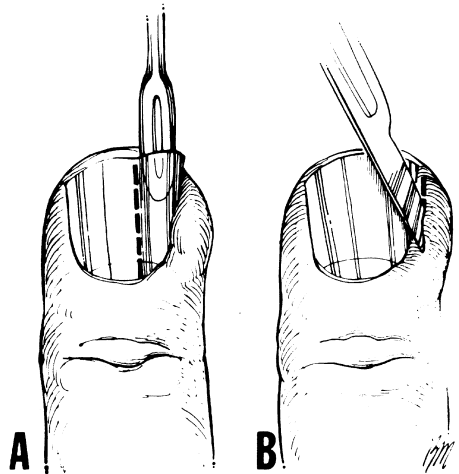
A paronychia is an infection around the fingernail, in the surrounding skin fold (eponychial fold). It usually is caused by *Staphylococcus aureus*. The skin around the proximal portion of the fingernail is swollen, and the finger is quite tender.

If the infection is caught early, the finger can be successfully treated by soaking it in warm, soapy water several times a day and giving oral antibiotics. If pus is present around the base of the nail, drainage is needed.

### *Drainage*

1. Anesthetize the finger with a digital block using lidocaine, bupivacaine, or a mixture of the two.
2. Soak the finger in warm, soapy water for 5–10 minutes.
3. Place the tips of a closed clamp under the skin fold around the nail to open the abscess. Wash the space out with saline, and then pack it with a small piece of gauze.
4. Remove the gauze the next day. Instruct the patient to continue the warm soaks and cover with antibiotic ointment and dry gauze 2 or 3 times/day.

Treatment of a paronychia. A, Elevation and removal of one-fourth of the nail to decompress the paronychium. B, Incision of the paronychial fold with the blade directed away from the nail bed and matrix. (Illustration by Elizabeth Roselius © 1998. From Green DP, et al (eds): *Operative Hand Surgery*, 4th ed. New York, Churchill Livingstone, 1999, with permission.)



5. If this approach does not lead to resolution of the infection, the skin fold may need to be incised and formally opened. The proximal part of the nail may need to be removed as well.

**Caution:** Be wary when a patient presents with an infection around the fingernail that does not seem like a “typical” infection. The finger may be swollen but not very tender, and small vesicles (blisters that are not pus-filled) are around the base of the nail. This presentation indicates a *herpetic* (viral) infection, which is seen most commonly in medical and dental personnel and people whose hands are often in water.

Do *not* incise and drain. Leave the vesicles alone. Incision and drainage carry a high risk for secondary bacterial infection, which can be quite difficult to treat. Herpetic infection is self-limiting and resolves in 3–4 weeks. If you have access to anti-herpes medications, oral treatment (acyclovir, 400 mg 3 times/day for 10 days) may relieve symptoms.

### ***Acute Suppurative Flexor Tenosynovitis***

The flexor tendons of the fingers travel within the confines of the surrounding flexor sheath. This anatomic arrangement allows the smooth gliding action of the flexor tendons, which is responsible for optimal finger flexion and hand function. The sheath around the flexor tendons of the fingers runs from the distal palmar skin crease of each finger to just proximal to the DIP joint flexion crease. It is essentially a closed space.

Acute suppurative flexor tenosynovitis is an infection within the confines of the flexor sheath. It is similar to an abscess and often requires drainage for resolution. Acute suppurative flexor tenosynovitis is potentially a serious infection and must be treated expeditiously. It can lead to the destruction of the gliding mechanism necessary for normal tendon function. If not treated appropriately, it can result in significant permanent limitation in finger and hand function.

#### *History and Physical Exam*

This infection is often associated with penetrating trauma to the finger. However, some patients cannot recall any significant antecedent injury.

#### *Cardinal Signs*

- Flexed posture of affected finger
- Diffuse swelling of the entire finger, which may extend to the dorsal surface of the metacarpophalangeal (MCP) area
- Significant tenderness along the volar aspect of the finger (where the tendon sheath is located)
- Pain with passive extension of the affected finger

The main area of tenderness, especially when the patient presents early in the course of the process, is over the A1 pulley. The A1 pulley represents the beginning of the flexor sheath, near the volar, distal palmar crease. Tenderness in this area is the most sensitive sign of acute flexor tenosynovitis and may help to differentiate it from other infectious processes involving the finger. For example, a felon or simple cellulitis of the finger does *not* have tenderness over this area.

If you are unsure of the diagnosis, you can treat conservatively with a splint, hand elevation, and antibiotics for 24 hours. You should splint the entire hand in neutral position. If symptoms improve, continue conservative management; if symptoms progress or do not improve significantly, operative exploration is necessary.

### *Operative Treatment*

Because of the potential for long-term disability if treatment is not prompt, drainage should be attempted if no specialist is available. If a specialist is available, refer the patient.

1. General anesthesia is best, but a wrist block may be used.
2. Use a tourniquet to keep blood out of the operating field and facilitate exploration of the finger. The tourniquet also helps to prevent accidental injury to digital nerves and vessels. With general anesthesia, place an upper arm tourniquet. With a wrist block, use a forearm tourniquet. *Do not exsanguinate the arm.*
3. Keep in mind that digital nerves and vessels run along the sides of the fingers.
4. Make a transverse incision in the DIP flexion crease. Use a clamp or blunt scissors to separate the soft tissues gently so that you can identify the distal portion of the flexor sheath. It is grayish and much thicker than normal (a few millimeters vs. < 1 mm).
5. Open this portion of the sheath.
6. Make a transverse counterincision in the palm over the distal palmar skin crease of the finger. It should not be too large (about 1.5 cm).
7. Carefully spread the soft tissues until you identify the sheath. It may appear gray and thick. Take care not to damage the digital arteries and nerves on either side of the sheath. Use blunt dissection, and do not cut *anything* until you are sure of what you are cutting.
8. If you have difficulty in identifying the sheath, extend the incision distally in a zig-zag fashion to improve access to the underlying tissues.
9. Open the sheath. Send a swab of the fluid from the sheath to the microbiology lab for analysis.

10. Place a catheter (20 gauge is best) similar to what you use for intravenous access into the sheath. Wash out the sheath by attaching a syringe with saline to the catheter and irrigating the sheath until the fluid that comes out is clear and no longer cloudy (cloudiness is due to the presence of pus in the canal). Irrigation fluid should come out of the distal incision by the DIP flexion crease.
11. If you had to extend the palm incision beyond the simple transverse incision, close the additional incision very loosely with one or two nonabsorbable sutures. Otherwise do not close either incision; the incisions will heal on their own.
12. The catheter should be left in place to allow irrigation of the sheath every few hours for the first 24 hours after surgery. If possible, attach the catheter to IV extension tubing so that a syringe can be attached outside the dressing.
13. Place a piece of gauze in each open wound.
14. Release the tourniquet, and apply gentle pressure over the incisions to control bleeding.
15. Place dry gauze between all fingers and around the affected finger.
16. Wrap the hand with soft gauze.
17. Splint the hand in neutral position.
18. Secure the IV tubing attached to the catheter in the flexor sheath to the outside of the splint so that it does not dislodge.

### *Postoperative Care*

1. The hand should be kept elevated in a splint.
2. Continue intravenous antibiotics. When the symptoms and signs of infection improve, change to oral antibiotics, and complete a 7–10 day course.
3. Irrigate the sheath with 3–5 ml of saline every 3–4 hours. Pain medication should be given before beginning irrigation.
4. Change the dressing after 24 hours, and remove the gauze packing and catheter at this time.
5. The patient should continue to wear the splint until the swelling and tenderness improve.
6. The patient should start passive and active motion once the swelling and tenderness improve.
7. The incisions heal on their own. The patient can apply antibiotic ointment after a few days and cover each incision with a bandage.

**Note:** There is no such thing as acute suppurative extensor tenosynovitis because there is no sheath around the extensor tendons of the fingers.

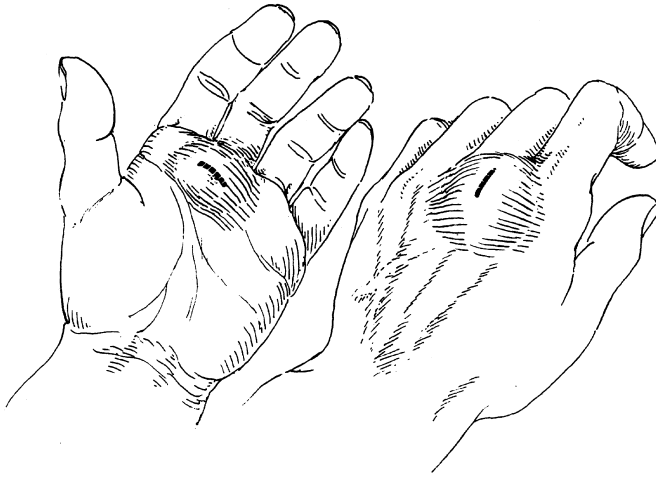
Patients with **rheumatoid arthritis** may develop a noninfectious tenosynovitis, which essentially is inflammation of the tendons caused by the underlying rheumatic disease. Often the tendons are involved more proximally at the wrist, and flexor or extensor tendons may be affected. This inflammatory disorder is quite different from an acute infectious process and does not require antibiotics or urgent surgical intervention. The symptoms are more chronic, and the physical findings are not as dramatic as those due to an infectious process.

### ***Abscess on the Dorsal Surface of the Hand***

The patient often presents with a very swollen hand and fingers. At first it may be difficult to appreciate the abscess cavity because of the diffuse nature of the swelling. In the presence of an obvious abscess, proceed to incision and drainage. If you are not certain whether or not an abscess is present, and the patient does not appear ill, treat conservatively at first with splint, hand elevation, and antibiotics for 1 day. Often after 24 hours of conservative treatment, the swelling decreases in areas not involved with the abscess. The abscess cavity is then identifiable.

#### *Incision and Drainage*

1. If the skin overlying the abscess is very thin (i.e., the abscess is “pointing”), no anesthetic may be required.
2. If the patient is in too much pain, local anesthetics may not be very useful because they do not work well in infected tissues. However, a block may work, or, if indicated by the extent of the abscess, general anesthesia may be required.
3. Make a longitudinal incision through the most fluctuant part of the abscess. Do not be timid when making the incision. Excise an ellipse of skin so that the opening is large enough to drain the abscess completely and to allow packing of the cavity with gauze.
4. Use the tips of a clamp to explore the abscess cavity. Make sure that the cavity does not extend to the volar side of the hand. If it does, a counterincision should be made over the volar extension of the cavity. This extension allows better drainage of the entire abscess. If you need to make a counterincision on the volar surface, first inject some anesthetic into the area.
5. Pack the wound with gauze.
6. Use a splint to keep the hand in neutral position.



A collar button abscess extends from the volar to the dorsal surfaces of the hand. Both sides of the hand must be drained individually because the two areas are connected by a narrow path. (From Chase RA: Atlas of Hand Surgery. Philadelphia, W.B. Saunders, 1973, with permission.)

### *Postoperative Care*

1. Keep the hand elevated and in the splint until the swelling and other signs of infection have improved.
2. The gauze packing should remain in place for 1 day. Then remove the gauze, and repack the cavity with saline-moistened gauze. Cover with dry gauze. This entire procedure should be done 2 or 3 times/day until the wound has healed.
3. The patient may wash the hand with gentle soap and water at each dressing change.
4. Antibiotics should be continued until the surrounding cellulitis resolves (probably only a few days).
5. Once the infection has resolved, the patient must start regular (several times per day) active and passive range-of-motion exercises to prevent permanent hand stiffness and limitation of hand function.

### ***Bibliography***

Neviaser RJ: Acute infections. In Green DP, Hotchkiss RN, Pederson WC (eds): Green's Operative Hand Surgery, 4th ed. New York, Churchill Livingstone, 1999, pp 1033-1047.